

Functional outcome of Unstable Inter-trochanteric femur fracture patients treated with Trochanteric fixation nail.

Yashwant J. Mahale,¹ Vikram V. Kadu¹

Abstract

Introduction: Inter-trochanteric fractures are disabling injuries that most commonly affect the elderly population. These fractures have a tremendous impact on both the health care system and society in general. These fractures can be managed by conservative methods, but mal-union and complications of prolonged immobilization is the result. Thus, surgery by internal fixation is the ideal choice. DHS was the gold standard treatment for inter trochanteric fractures before intra-medullary devices were developed. These devices have the advantage of shorter lever arm causing less tensile strain on the implant, controlled fracture impaction due to incorporation of sliding hip screw, shorter operative duration and less soft tissue dissection. In view of these considerations, present study is taken up to assess the outcome in terms of adequacy of fixation and results.

Methods: This is a retrospective study including 40 patients of unstable inter-trochanteric fracture treated with trochanteric fixation nail. Mean age group of patient was 61.78 years.

Results: Functional results were assessed in all 40 cases at follow up. Excellent results were noted in 27 cases, good in 10, fair in 3 and none had poor result. Anatomical results were assessed by presence or absence of shortening and range of movements.

Conclusion: The trochanteric fixation nail is a good minimally invasive implant for unstable inter-trochanteric fracture with less blood loss and soft tissue damage.

Key Words: Unstable inter-trochanteric fractures, shortening, trochanteric fixation nail.

Introduction

The incidence of inter-trochanteric fracture has increased significantly during recent years due to the advancing age of the world's energy trauma, whereas in the elderly age group most of the fractures are osteoporotic, resulting from a trivial fall. [1] Complications of conservative management such as mal-union and prolonged immobilization has made internal fixation the ideal choice. DHS is the gold standard treatment for inter-trochanteric fractures. [2] In cases of unstable inter-trochanteric fractures with DHS, the incidence of limb shortening, medialization of distal fragment and implant cut-outs is high. [1] This led to the development of intramedullary devices. Numerous variations of intramedullary nails have been devised to achieve a stable fixation and early mobilisation of trochanteric fractures. Among these the trochanteric fixation nail (TFN) devised by the AO/ ASIF group in 1996 has proven to be a promising implant in per-, inter- or subtrochanteric femoral fractures. [3] These devices have the advantage of being an intermedullary fixation device, shorter operative duration, less blood loss and less soft tissue dissection. Purpose of the Study: To study the outcomes in

terms of adequacy of fixation and stability and to evaluate end results and complications using trochanteric fixation nail.

Material and Methods:

The study consisted forty cases of unstable inter-trochanteric fractures of femur treated surgically with Trochanteric fixation nailing at our institute between 2012 to 2014. The fractures were classified according to Boyd & Griffin's classification. Type-IV cases were mainly excluded because of extension of the fracture onto the proximal shaft since problems were encountered with fixation of the distal locking screw which mainly crossed the fractured fragment while using conventional TFN (180mm). All the 40 Patients were available for follow-up.

The age of the patients ranged from 30 years to 88 years, average being 61.78 years. The study consisted of sixteen females and twenty four males. The most common mode of injury in our series was trivial fall accounting for 26 cases, followed by road traffic accidents in 14 cases. Right side was affected in 19 cases and left in 21 cases. This study was conducted with due emphasis for clinical observation and

analysis of result after surgical management of unstable inter-trochanteric fractures of femur with Trochanteric fixation nail. Following the treatment, patients were discharged and followed up at regular intervals for clinical and radiological evaluation. The patients were followed up till fracture union and functional recovery. If necessary, subsequent follow up was done. At the arrival of the patient with suspected trochanteric fracture, patients were resuscitated depending

¹ACPM Medical College , Dhule - 424001 , Maharashtra India.

²Mahale Accident Hospital , Dhule, Maharashtra India.

Address of Correspondence

Dr. Vikram V Kadu
C/O Vilas Shamrao Kadu, Plot no. 20, Kadu House, Barde layout, Katol Road, Nagpur - 440013
Email: vikram1065@gmail.com



Dr. Yashwant J. Mahale



Dr. Vikram V. Kadu

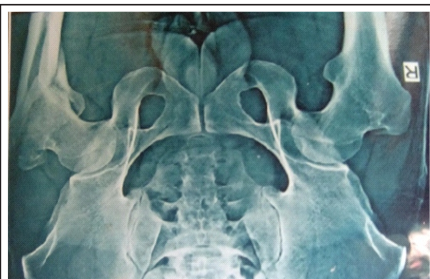

Fig. 1: Pre-Operative Radiograph

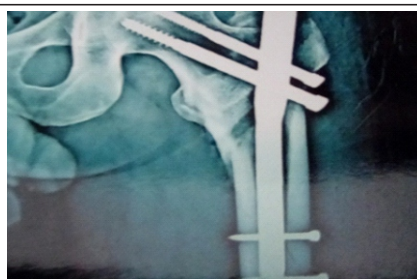


Fig. 2: Immediate Post-Op

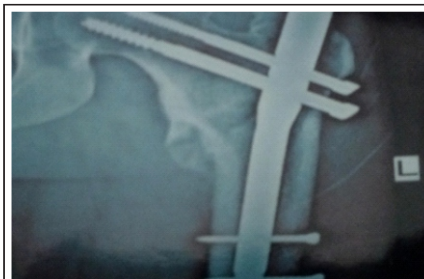


Fig. 3: 3 Months Post-Op

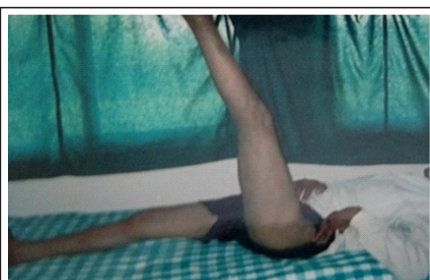


Fig. 4: Rom at 6 Months

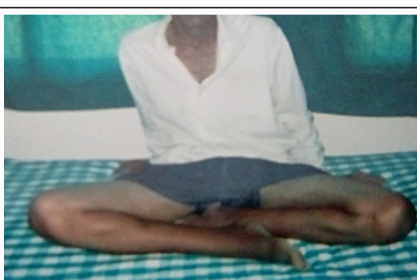

Fig. 5: Rom at 6 Months

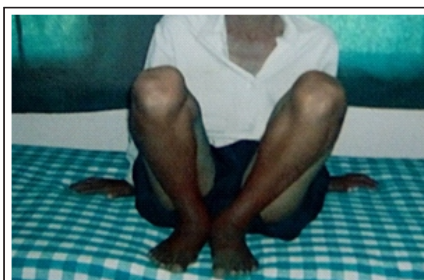

Fig. 6: Rom at 6 Months

on their general conditions. Fractures were stabilized using skin traction, alternatively with Thomas Splint.

A thorough preoperative assessment of patients were done, which included general condition of patients, clinical and radiological assessment of fractures, type and size of fragments. Once stabilized, all the patients were shifted to ward. Associated injuries were evaluated and treated simultaneously. Functional results were assessed based on the functions gained by the patients following surgery and points were awarded accordingly. The factors taken into consideration in assessing were Hip pain, Ambulatory status, Ability to squat, Walking distance, Sitting cross legged.

Results

Surgery was performed on average of 2 days with a range of 1-4 days. The delay was due to the general and medical conditions of the patients and managing associated injuries. Duration was longer in managing inter-trochanteric with subtrochanteric extension fractures type III, due to the difficulty in achieving anatomical reduction. Blood loss was measured in terms of mop count and suction collection. The average amount of blood loss was 80 ml (range 60-120ml).

In our series we had 2 cases of superficial wound infection which required appropriate antibiotics and 1 case of varus collapse was noted with shortening of up to 1cm. The average duration of hospital stay following surgery was 5 days. Physiotherapy was started on day 1 which included quadriceps strengthening exercise, knee bending exercises and chest physiotherapy. Patients were instructed non weight bearing or partial weight bearing with walker depending on the post-op radiological picture and pain tolerability. Weight bearing was increased at subsequent follow up. The average duration of follow up was 3 months ranging from 1-6 months, of which all the patients were available for follow-up. Radiological union was said to be achieved on the evidences of presence of bridging callus and

haziness of the fracture line on antero-posterior and lateral radiographs. 30 cases showed union at 3 months, 9 cases showed union at 4 months duration and 1 case showed union at 5 months duration. Anatomical results were assessed by presence or absence of shortening, deformities and range of movements.

Discussion

Inter-trochanteric fractures of the femur are relatively common injuries among the elderly individuals. Sometimes the associated generic problem makes it a terminal event in the lives of elderly individuals. In order to reduce the morbidity and mortality associated with conservative management of inter-trochanteric fractures, surgical management of the inter-trochanteric fractures is advocated as the best modality of management for these fractures. Inter-trochanteric fractures almost invariably occur as a result of a fall, involving both direct and indirect forces. [4,5] Mulley and espley [6] demonstrated that inter-trochanteric fractures which occurred in hemiplegic patients sustained a trauma directly over the side secondary to impaired locomotor function and discusses osteoporosis on that side. Direct force act along the axis of the femur or directly over the greater trochanter to result in an inter-trochanteric fracture. Indirect forces include pull of the iliopsoas muscle on the lesser trochanter and the abductors on the greater trochanter have also been incriminated as a cause of the fracture. [4]

When there is cortical instability on one side of a fracture due to cortical overlap or destruction, a fracture tends to collapse in the direction of such instability. [7] A truly stable inter-trochanteric fracture, therefore, is one that, when reduced, has cortical contact without a gap medially and posteriorly. [8,9]

Early operative treatment of trochanteric fractures reduces both mortality and morbidity (laskin, gruber and Zimmerman,1979) giving best chance of early independence and reducing the risk of prolonged bed rest. In the management of inter-trochanteric

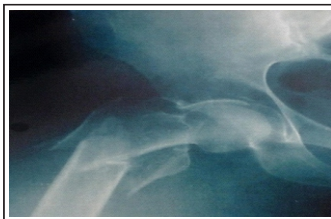

Fig. 1: Pre-Operative Radiograph

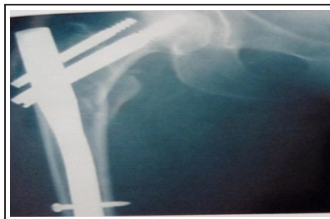


Fig. 2: Immediate Post-Op

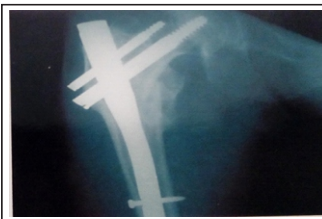

Fig. 3: 3 Months Post-Op

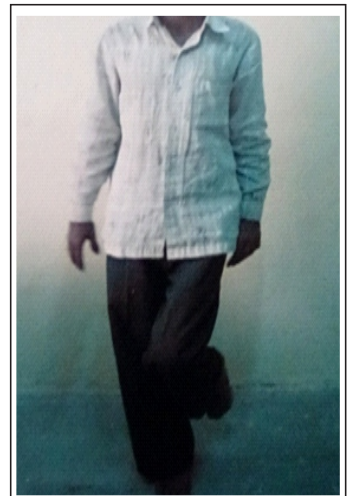


Fig. 7: Rom at 6 Months

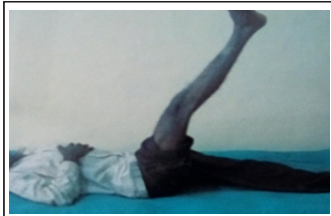

Fig. 4: Rom at 6 Months



Fig. 5: Rom at 6 Months

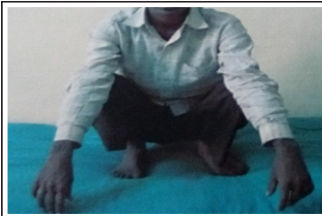

Fig. 6: Rom at 6 Months

fractures of femur, it is important to re-establish bone to bone contact to the postero-medial cortex.

The trochanteric fixation nail (TFN) AO-ASIF device introduced in 1996 was designed to reduce the risk of implant complications. Studies have shown that screw cut out occurred by varus collapse and concomitant rotation of the femoral head around the neck axis (Seral B et al 2004, Sommers MB et al 2004) therefore in addition to the 8mm load bearing femoral neck screw, the TFN has a 6.5 mm autorotation screw to increase the rotational stability of the fragment. The derotation screw is inserted first to prevent possible rotation of the proximal fragment at the time of insertion of hip screw. An anatomic 6 degree neck valgus bend in the coronal plane, a narrower distal diameter and distal flexibility of the nail eliminates the need for routine reaming of the femoral shaft and also minimizes stress concentration and postoperative femoral shaft fractures. In cases of unstable inter-trochanteric fractures the incidence of limb shortening, medialization of distal fragments and implant cut-outs is high. This led to the development of intramedullary devices. These devices have the advantage of shorter lever arm causing less tensile strain on the implant, controlled fracture impaction due to incorporation of sliding hip screw, shorter operative duration and less soft tissue dissection. The average duration of radiation exposure was 25 seconds in cases of TFN which is comparatively more as

compared to DHS plating which averages to 40 seconds. [10] Amount of blood loss using trochanteric fixation nail was very less 80 ml as compared to DHS plating with average to 300ml. [11] Trochanteric fixation nail attempts to combine the advantages of a sliding lag screw with those of intramedullary fixation. It is inserted by a closed procedure which retains the fracture haematoma, and is an important consideration in fracture union (MC Kibbin 1978) and reduces both exposure and dissection. Failure of fixation was seen in one case of varus collapse due to excessive comminution of the fracture. Patient was managed with regular follow up to wait for the fracture to unite & subsequently implant removal.

Conclusion:

Trochanteric fixation nail is a novel implant based on the experience of gamma nail. In the light of these results, one can conclude that the TFN is a satisfactory method in treating unstable IT fractures. It requires closed monitoring during pre, intra and post-operative period to avoid complications, which can be easily managed. It however requires large study population with a long term follow-up.

Ethical statement: All procedures were in accordance with the ethical standards of the institutional and / or national research committee.

References

1. Robert W Bucholz, James D Heckman, Charles M Court-Brown, Rockwood and Greens volume 2, 6th edition; pages 1827-44
2. GS kulkarni, Rajiv Limaye, Milind Kulkarni, ' intertrochanteric fractures- Current concept review' Ind J Orth, 2006, vol 40, 16-23
3. Boldin, Christia, Seibert, Franz J, Fankhauser, Wolfgang, Szyszkowitz, Rudolf (2003) et al. Acta Orthopaedics, 74:1, 53-58
4. Ganz R, Thomas R, Hammerle CP. Clin Orthop 1979; 138:30-40
5. Cleveland, M. Bosworth, D. M and Thompson, F.R. JBJS, 29:1049-67, 1947
6. Mulley G and Espley, A. J. Postgrad Med. J, 55:264-265, 1979
7. Evans EM. JBJS 1949; 31B: 190-203
8. Wolfgang GL. Clinical Orthopaedics and related research 1982; 163: 148-158
9. Sarmento, A. Clin.Orthop, 53:47-59, 1967.
10. Wei-Chao Sheng, Jia-Zhen Li, Sheng-Hua Chen and Shi-Zen Zhong. International orthopaedics, vol 33, number 2, 537-42
11. Patil Suresh S, Panghate Atul. J orthopaedics 2008, 5(3) E7.

Conflict of Interest: NIL
Source of Support: NIL

How to Cite this Article

Mahale YJ, Kadu V. Functional outcome of Unstable Inter-trochanteric femur fracture patients treated with Trochanteric fixation nail.. Trauma International May-Aug 2018;4(1):22-24.