Cannulated Cancellous Screw and Ender's Nail Fixation in Stable Intertrochanteric Femur Fracture in Elderly Patient With Co-Morbid Condition

Rohan R Memon[1], Drashtant Patel[1]

Abstract

Introduction: Intertrochanteric Femur fracture is common in elderly patient with co-morbidity.Ender and Simon Weidner popularized the concept of closed condylocephlic nailing for intertrochanteric fractures in 1970. The clinical experience of authors revealed that Ender nailing alone cannot provide secure fixation in elderly patients with osteoporosis.

Aims and objectives: we conducted a study to evaluate the efficacy of a combined fixation procedure using Ender nails and a cannulated compression screw for intertrochanteric fractures.

Study Design: This is a prospective observational type of study

Place and duration of study:Dept of orthopaedics,NHL medical college between January 2015 to June 2018

Methodology: 52 patients with intertrochanteric fractures were treated using intramedullary Ender nails and cannulated compression screw from January 2015 to june 2018. We included those patients having age ≥50 years, with multiple co- morbid conditions like diabetes, hypertension, COPD, Asthma, bleeding disorders and multiple fractures, and duration of the Intertrochanteric fracture ≤ two week. We exclude young active patients < 50 yrs age, fracture > 2 weeks duration, fracture with lateral wall comminution and open fractures. The two Ender nails of 4.5mm each were passed across the fracture site into the proximal neck. This was reinforced with a 6.5 mm cannulated compression screw passed from the sub trochanteric region, across the fracture into the head.

Results: All the fractures were united within an average period of 13 weeks with a range of 10 – 13 weeks. The functional assessment was done with modified Harris hip score(Table no 1,2) and the mean was 86.3 with a range from 73 to 95 , and 26 patients were excellent, 20 patients were good , 4 patients were fair and two patients were poor with respect to total score. The analysis of this study fulfils the objectives of good functional outcome

Conclusions: The Ender nailing combined with compression screw fixation in cases of intertrochanteric fractures in high risk elderly patients could achieve reliable fracture stability with minimal complications.

Keywords: Compression screw, Ender nails, osteoporosis, inter-trochanteric fracture

Introduction

Intertrochanteric fracture of femur involves those occurring in the region extending from the extracapsular basilar neck region to the region along the lesser trochanter, proximal to the development of the medullary canal. fragments.The Intertrochanter femoral fractures make up approximately 34% of all hip fractures(1) and the largest number of fractures occur in female older than 65 years(2,3,). The intertrochantreic fracture were more common in severely osteoporotic women(4). The treatment of intertrochanteric fracture evolves from non-operative to operative over decades. Nonoperative treatment with traction and prolonged bed rest should only be considered in non-ambulatory or severely demented patients with controllable pain, or patients with terminal disease with less than 6 weeks of life expected. Operative management, which allows early rehabilitation and offers the best chance for functional recovery , is now the treatment of choice for virtually all intertrochanteric Femur fractures. The goal of operative treatment is strong, stable fixation of the fracture fragments. The Ender nail for intramedullary fixation of intertrochanteric fractures of the femur was developed by Ender and Simon Weidner 5 and further simplified by Kuntscher. The tensile property of the nail combined with the simplicity of the procedure and feasibility of early ambulation led to the nail becoming popular among hip surgeons. However, the nail ran out of favor on account of its failure to control rotation and distal migration in previous series. Bearing this in mind, we added a cannulated compression screw to the Ender nails in an attempt to maintain fracture reduction. Hence a study regarding the feasibility of a combined procedure in high risk elderly cases was conducted.

[1]Department of orthopaedics, VS General hospital,NHL Medical college. Ahmedabad

Address of Correspondence
Dr. Rohan Rafik Memon,
Department of orthopaedics, VS General hospital,NHL Medical college. Ahmedabad
Email: rhnmemon222@gmail.com

Materials and Methods

This is a prospective observational study that was conducted in the Department of Orthopedics, In VS General hospital, Ahmedabad during the period of January 2015 to june 2018. The study includes 52 Patients with intertrochanteric fractures of femur ,attending

Harris Hip Score

Hip ID:

Study Hip: ☐ Left ☐ Right

Examination Date (MM/DD/YY): / /

Subject Initials: |___|___|___|

Medical Record Number:

Interval: _____

Harris Hip Score

Pain *(check one)*

- ☐ None or ignores it (44)
- ☐ Slight, occasional, no compromise in activities (40)
- ☐ Mild pain, no effect on average activities, rarely moderate pain with unusual activity; may take aspirin (30)
- ☐ Moderate Pain, tolerable but makes concession to pain. Some limitation of ordinary activity or work. May require Occasional pain medication stronger than aspirin (20)
- ☐ Marked pain, serious limitation of activities (10)
- ☐ Totally disabled, crippled, pain in bed, bedridden (0)

Limp

- ☐ None (11)
- ☐ Slight (8)
- ☐ Moderate (5)
- ☐ Severe (0)

Support

- ☐ None (11)
- ☐ Cane for long walks (7)
- ☐ Cane most of time (5)
- ☐ One crutch (3)
- ☐ Two canes (2)
- ☐ Two crutches or not able to walk (0)

Distance Walked

- ☐ Unlimited (11)
- ☐ Six blocks (8)
- ☐ Two or three blocks (5)
- ☐ Indoors only (2)
- ☐ Bed and chair only (0)

Sitting

- ☐ Comfortably in ordinary chair for one hour (5)
- ☐ On a high chair for 30 minutes (3)
- ☐ Unable to sit comfortably in any chair (0)

Enter public transportation

- ☐ Yes (1)
- ☐ No (0)

Stairs

- ☐ Normally without using a railing (4)
- ☐ Normally using a railing (2)
- ☐ In any manner (1)
- ☐ Unable to do stairs (0)

Put on Shoes and Socks

- ☐ With ease (4)
- ☐ With difficulty (2)
- ☐ Unable (0)

Absence of Deformity (All yes = 4; Less than 4 =0)

Less than 30° fixed flexion contracture	☐ Yes	☐ No
Less than 10° fixed abduction	☐ Yes	☐ No
Less than 10° fixed internal rotation in extension	☐ Yes	☐ No
Limb length discrepancy less than 3.2 cm	☐ Yes	☐ No

Range of Motion (*indicates normal)

Flexion (*140°) _____

Abduction (*40°) _____

Adduction (*40°) _____

External Rotation (*40°) _____

Internal Rotation (*40°) _____

Range of Motion Scale

211° - 300° (5)	61° - 100 (2)
161° - 210° (4)	31° - 60° (1)
101° - 160° (3)	0° - 30° (0)

Range of Motion Score _____

Total Harris Hip Score _____

Table 1: ?

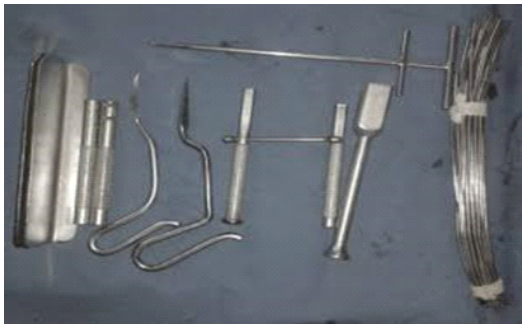

Figure 1: ?

Figure 2: positioning the patient

Figure 3: painting and draping done

Orthopaedics outdoor and emergency department in this hospital. Patients were evaluated regarding pre-injury mobility status on the basis of their ability to walk within their place of residence. The presence of co-morbidities like diabetes mellitus (n=29), hypertension (n=11), COPD (n=05), ischemic heart disease (n=04), CVA (n=2) and history of previous coronary artery bypass surgery (n=1) were also included. We exclude young active patients < 50 yrs age, fracture > 2 weeks duration, fracturewith lateral wall comminution and open fractures. The affected limb was thoroughly examined to rule out vascular or neurological injury. Ipsilateral knee and spine examined for associated injury. Anteroposterior radiograph of pelvis showing both hips, and lateral view of involved proximal femur were obtained.

2.1 Implants Used For Fracture Fixation (Figure :1)

4.0/ 4.5 mm Ender's nails, 6.5mm cannulated cancellous screws and Instrumentation set

Surgical Technique

After proper anaesthesia, patients were positioned on a fracture table in supine position. Both the legs were widely abducted and feet were fixed in the boots of the traction device of the fracture table. Closed reduction of the fracture was done by combination of traction and rotation under image intensifier control in both anteroposterior and lateral views. After proper draping, a longitudinal skin incision 5-7 cm long, beginning just distal to the medial epicondyle and extending proximally, was made.The deep fascia was splitted just anterior to the medial inter-muscular septum, and the vastus medialis was reflected anteriorly to expose the femur subperiosteally, just above the superior medial geniculate artery, with special care to it. With drill or awl an opening is made, which is at least 15 mm wide, to accommodate three to four 4.0/ 4.5 mm Ender's nails side by side. Three Ender's nails of proper size were inserted, making an effort to fan within neck and head of femur in both AP and Lateral view. The first nail's tip is slightly anteverted. Distally, the nails should lie flushed with the medial cortex of the femur, above the epicondyle. One or two 6.5 mm cancellous cannulated screws are introduced from base of greater trochanter in the head of femur under image intensifier control, through a small incision at lateral side of thigh

Intra operative photos

Postoperative rehabilitation protocol

Quadricep strengthening exercises were encouraged from the first postoperative day. Non-weight bearing ambulation touch toe using a walker was permitted in self confident patients by the 10th post-operative day. Patients were called for review after a month and assessed clinically for any limb length discrepancy and mal alignment of the limb. Radiological assessment was done to verify the position of the implant as a check to compliance with the postoperative ambulation protocol. During the first followup at one month xray pelvis with both hips anteroposterior (AP) view and involved hip lateral was done. Partial weight bearing was initiated after the sixth week. It was gradually progressed to full weight bearing as per tolerance and absence of radiological evidence of collapse. Successive reviews were done at six-week intervals during which rotations in flexion/extension, limb length discrepancy and knee range of motion were assessed. In the event of patient complaining knee pain, X-ray distal femur with knee AP was done.

Total Harris hip score is interpretated as excellent when score is 90 to 100, as good when score is 80

to 89, as fair when score is 70 to 79, and as poor when score is less than 70

Observations and analysis

In our study, 52 patients were studied. Among them 85% of the patients were in the age group more than 70 years and 15% of the patients were

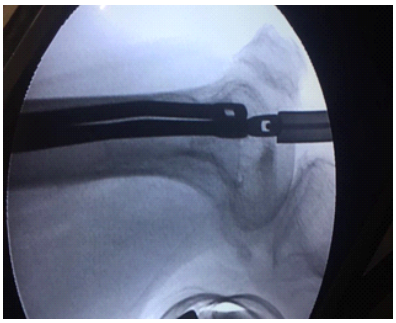

Figure 4: Insertion of the nail

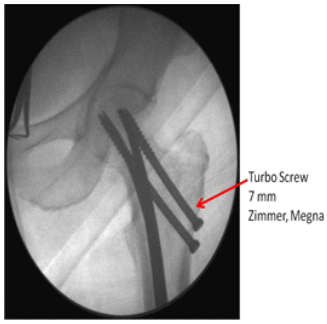

Figure 5: Intraoperative iitv image

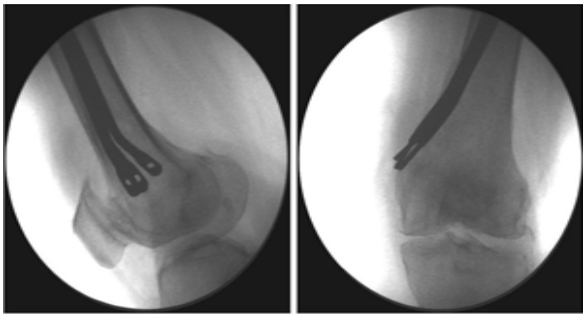

Figure 6: Intraoperative iitv image

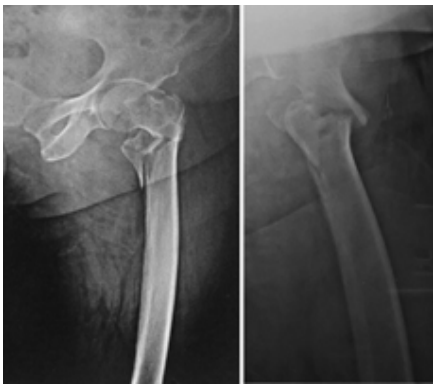

Figure 7: Preoperative xray

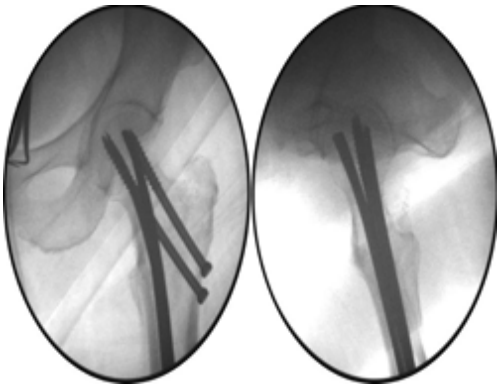

Figure 8: postoperative xray

Figure 9: 6months follow up

in the age group less than 70 years , with mean age of approx. 72 yrs. This indicate that maximum patients are elderly and have same physiological age, and the intertrochanteric fractures are more common in elderly. In our study both right and left side were equally involved. Among co-morbidities , diabetes and hypertension were most frequently associated (>90%). This indicate that systemic medical illness may have impact on intertrochanteric fracture. In our study, low velocity trauma (LVT) was the most common(70%) mode of injury. This indicate that decreased bone mass index with age, especially in females, and poor protective responses with age, causes fractures with simple trauma. In our study , 35% patients were operated within a week and 65% patients were operated after a week. This may be due to the fact that all patients had pre-existing co morbidities which had taken time for optimization prior to surgery.

In the post-operative period, antibiotic and analgesic coverage for seven days were given. Hip and knee physiotherapy were started from the next post-operative day. All the patients were discharged after assessment of wound at first postoperative dressing. Sutures were removed after two weeks. Non- weight bearing walking with bilateral axillary crutch were allowed after effect of spinal anaesthesia was over i.e after 48-72 hrs. The patients were followed up regularly at 4 week intervals for the first 6 months , and then at 3 month intervals. At each follow- up, patient was assessed clinically, radiologically and functionally. Radiological assessment was done by digital X- ray of pelvis with both hip AP view ,and Lateral view of the operated hip with femur. Knee was also X-rayed as and when indicated. Functional assessment was done by modified Harris hip score. In our study all fractures were united within an average period of 13 weeks, with a range 10 – 13 weeks. The average neck- shaft angle of the fractured hip in the last follow- up X-ray was 128.55 degree, with a range of 115 to 135 degree. The average difference between the neck- shaft angle of fractured side and the normal side, in the last follow up Xray was 4.80 degree. Partial weight bearing walking was allowed after assessing for radiological and clinical union, usually at 12 to 14 weeks. Full weight bearing was achieved within 6 to 9 months in all patients

In our study all the fractures were united, but two of them were united with external rotation deformity and seven of them had varus deformity with decreased neclk shaft angle. In our study, 60% of the patients had no leg- length discrepancy, 35% of the patients had leg-length discrepancy less than one cm, and 5% of the patients had leg-length discrepancy of 1.5 cm which was managed by shoe raise. The functional assessment was done with modified Harris hip score(Table no 1,2) and the mean was 86.3 with a range from 73 to 95 , and 26 patients were excellent, 20 patients were good , 4 patients were fair and two patients were poor with respect to total score(Table no 3,Graph no 1). The analysis of this study fulfils the objectives of good functional outcome

Discussion

Many types of internal fixation devices have been introduced for intertrochanteric fracture. Any surgical treatment with fixation devices

Figure 10: 1 year follow up xray

Figure 11: Cross legged sitting

Figure 12: Hip and knee flexion

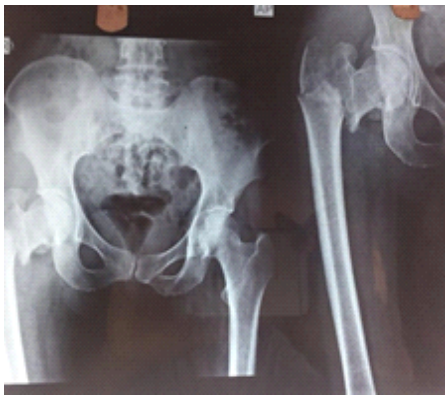

Figure 13: preoperative xray

Figure 14: postoperative xray

Figure 15: 6 months followup

for this fracture should provide sufficient fixation of the fracture to allow early mobilization of the fractured limb, to obtain fracture union, and to minimize the complications such as delayed union or nonunion, penetration of the nail into the hip joint and distal migration. In patients with osteoporosis, any single type of internal fixation device cannot provide secure fixation of the fracture, resulting in loss of the reduced position together with migration of the nails[6] Presently, intertrochanteric fractures are fixed either with dynamic hip screw or proximal femoral nail[7] Both these methods though providing secure fixation have their drawbacks. Dynamic hip screw (DHS) is complicated by joint penetration and cut out in osteoporotic patients[8]. Both these complications are catastrophic for the patient and surgeon. DHS also entails significant blood loss and traumatic in high risk cases. Proximal femoral nail (PFN) is technically demanding and dependent on the status of pyriform fossa. In a patient with fracture involving pyriform fossa, PFN is not ideal. PFN also carries an unacceptably high risk of fracture of femur at the tip of the nail[9]. Ender nails alone have also been used in fixation of intertrochanteric fractures[10]. Past authors reported an unacceptably high failure rate with Ender nails alone[11]. The Ender nail used alone did not provide rotational stability and was associated with an increased risk of migration and joint penetration proximally or distally[12]. By incorporating the tensile property of Ender nails along with a compression screw, fracture reduction and prevention of rotation respectively were possible[13]. This combination tended to augment the fracture stability in presence of osteoporosis[14]. However, the combined procedure brought successful union in all cases which could be listed as a merit[15]. In none of this series did the nail tips penetrate or cut the head. The comparative common postoperative complaints were pain around the knee joint and minimal residual stiffness of the knee. Combination fixation of intertrochanteric fractures with Ender nails and compression screw is technically less demanding, minimally invasive, entails less operative time (beneficial factor in high risk cases) and least traumatic with minimal blood loss. This method can be used irrespective of the status of pyriformis fossa and has proved to be an ideal alternative procedure for fixation of intertrochanteric fractures in elderly patients with high risk co-morbidities and osteoporosis

Conclusion

In our study,combining the use of intramedullary implant Ender's nail and cannulated cancellous screw, and after analysing the result of this study and comparing with other studies[16], conclusions are as follow- 1)This method of closed reduction and internal fixation provide good functional recovery in elderly patients. 2)This method of operation is technically easy, minimally invasive, taking less intra-operative time, and having less intra-operative blood loss and other complications. 3). This method of operation have less post-operative infections.4) The use of Cannulated Cancellous Screws passed along with Ender's nail helps in Controlled Collapse of the fracture and keeps the fracture reduced and fixed in anatomical position. This method provides good axial and rotational stability The advantages are remote reduction and atraumatic intramedullary fixation through a small opening far distal

Figure 16: Cross legged sitting

Figure 17: Squatting

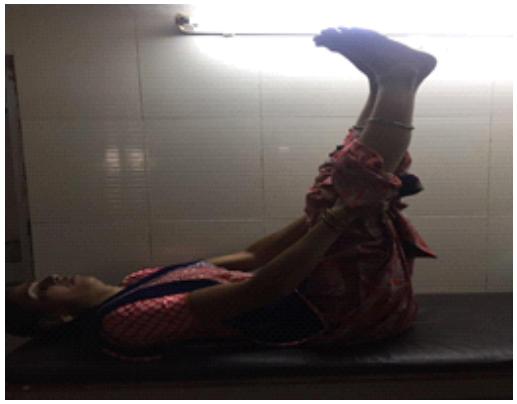

Figure 18: straight leg raisng

from fracture site, decreased blood loss, deceased mortality, minimal surgical trauma secondary to not opening the fracture site, and decreased anaesthetic and operative time .Theintramedullry implants are biomechanically more acceptable particularly regarding bending stress at weight bearing site[17]. Because of their fan- shaped positioning in the femoral head , the Ender's nail guarantee a good grip in the proximal fragment, and transfer the force during weight bearing process to the entire length of femoral shaft. Ender's nail allow good surface contact of the fracture site by collapsing the fragments along the nails; this may cause their ends to back- out by a few mm at the entrance hole, without, however causing knee pain. Mechanically, this system is advantageous because of the medial course of the nails and the low bendingstress imposed on them[18]. Bio- dynamically, it is advantageous because the fracture site takes an active part in theweight bearing process because of the telescoping effect, and is brought under physiologic compression becauseof the muscle tension and weight bearing. Thus for the treatment of intertrochanteric fractures in elderly patients with co-morbidity, the combined use of Ender's nail and cannulated cancellous screw may provide good fracture reduction and stability and good functional outcome.

References

1. Rockwood and Green;s Fracture in adults, 8th edition: vol.2:2075-2130.
2. Hagino H, Furukawa K, Fujiwara S, et al. Recent trend in the incidence and lifetime risk of hip fractures in Tottori, Japan.Osteoporos Int. 2009;20(4):543-548.
3. Lawton JO, Baker MR, Dickson RA. Femoral neck fracture: two populations. Lancer 1983;2:70-72.
4. Atkin JM. Relavance of osteoporosis in women with fractures of the femoral neck. Br Med J 1984;288':597-601.Pogrund H, Makin M, Robin G, et al. Osteoporosis in patients with fractured femoral neck in Jerusalem. Clin Orthop 1977;124:165-172.
5. Ender J, Simon-Weidner R. Die Fixierung der trochantener bruche mit runden elastischen Kondylennageln. Acta Chir Austria1970;1:40.
6. Bonnaire F, Weber A, Bosl O, Eckhardt C, Schweiger, Linke B. "Cutting out" in pertrochanteric fractures – problem of osteoporosis. Unfallchirurg. 2007;110:425–32.
7. Beidle SH, Patel AD, Bircher M, Calvert PT. Fixation of intertrochanteric fractures femur – randomized prospective comparison of gamma nail and dynamic hip screw. JBJS Br. 1991;73:330–4.
8. Nordin S, Zulkifil O, Faisham WI. Mechanical failure of DHS fixation in intertochanteric fracture femur. Med J Malaysia. 2001;56:12–7.
9. Fogognolo F, Kfuri M, Jr, Paccola CA. Intramedullary fixation of pertrochanteric hip fractures with PFN. Arch Orthop Trauma surgery. 2004;124:31–7.
10. Wojcik B, Tokarowski A, Swieboda A, Kaleta M, Nowak R. Endernails in the stabilization of trochanteric fracture in elderly. Chir Narzadow Ruchu Ortop Pol. 1999;64:279–83.
11. Raughstad TS, Moister A, Haukeland W, Hestenes O, Olerud S. Treatment of petrochanteric and subtrochanteric fractures of the femur by the Ender metod. Clin Orthop. 1970;138:321.
12. Pankovich AM, Tarabiski IE. Ender nailing of intertrochanteric fractures of femur. J Bone Joint Surg. 1980;62A:635.
13. [13].Cobelli NJ, Sadler AH. Ender rod versus compressive screw: fixation of hip fracture. Clin Orthop. 1970;138:321
14. Moon MS, Woo YK, Kim ST. A clinical study of trochanteric fractures of the femur: Outcome of the treatment in regard to osteoporosis and type of the treatment. I Korean Orthop Assoc. 1991;26:1693–702.
15. Russian LA, Sonni A. Treatment of intertrochanteric and subtrochanteric fractures with Ender intramedullary rods. Clin Orthop. 1980;148:203–12.
16. Kuderna H, Bohler N, Colby AJ. Treatment of intertrochanteric and subtrochanteric fracture of the hip by the Ender method. J Bone Joint Surg. 1976;58:604–11.
17. Hall LG. Comparison of nail-plate fixation Ender's nailing for intertrochanteric fractures. J Bone Joint Surg. 1981;63-B:24–8.
18. Parker MJ, Handoll HH, Bhonsle S, Gillespie WJ. Condylocephalic nails versus extramedullary implants for extracapsular hip fractures. Cochrane Database Syst Rev. 2000;2:CD000338.

Conflict of Interest: NIL
Source of Support: NIL

How to Cite this Article

Memon R R, Patel D. Cannulated Cancellous Screw and Ender's Nail Fixation in Stable Intertrochanteric Femur Fracture in Elderly Patient With Co-Morbid Condition. Journal of Bone and Joint Diseases Jan - Apr 2019;5(1):17-22.