

# Resource Utilization and Ethics of Urgent Orthopedic Spine Surgery During the COVID-19 Pandemic: A Case Report

Matthew J. Partan<sup>1,2</sup>, Peter B. White<sup>1,2</sup>, Randy M. Cohn<sup>1,3,4</sup>,  
Gus Katsigiorgis<sup>1,4</sup>, Kanwarpaul Grewal<sup>1,2,4</sup>

## Abstract

**Introduction:** Severe acute respiratory syndrome coronavirus-2 (SARs-CoV-2), also known as a coronavirus disease-19 (COVID-19), is a novel respiratory disease that has quickly surmounted to pandemic proportions. The purpose of this case report is to discuss the decision-making process, and resource utilization for spine cases that necessitate urgent surgical intervention in light of the COVID-19 pandemic.

**Case Presentation:** A twenty-five-year-old Hispanic male presented to an emergency department in Long Island, New York on March 30th, 2020 with incomplete cauda equina with altered bladder function. An MRI revealed a moderately large central disc extrusion of L4/5 with deformation at the ventral thecal sac which resulted in severe spinal stenosis. Given displacement of immediately available resources, the patient required a transfer to an affiliate hospital with readily available operating room staff.

**Conclusion:** From the time of initial presentation to the emergency room the patient was successfully transferred and brought to the operating room suite within eight hours. The patient underwent an L4/5 decompression and microdiscectomy for a large extruded disk herniation at L4/5 level without complications. With our healthcare system in the epicenter of the COVID-19 pandemic, we are in a unique environment exposed to the harsh characteristics of the surge. In parallel with similarly challenged organizations, our system quickly adapted and adopted various guidelines and committees to organize resource allocation. As demonstrated in this case, the displacement of immediately available resources, such as anesthesia staff, placed strain on the routine workings of surgical coordination. In normal times the decision-making in this case may seem straightforward; however, this case demonstrates the strains that the COVID-19 pandemic placed on our healthcare system especially with regards to surgical acuity, COVID-19 exposure risk and resource allocation.

**Keywords:** Cauda equine; Spine; Medical ethics; COVID-19.

### Introduction:

Severe acute respiratory syndrome coronavirus-2 (SARs-CoV-2), also known as a coronavirus disease-19 (COVID-19), is a novel respiratory disease that has quickly surmounted to pandemic proportions [1]. As of March 2020, the New York Metropolitan area and our institution has been the epicenter for COVID-19 in the United States [1,2].

Although physicians are trained with a patient-first mentality, pandemics such as this call for a more public health focus. Under this framework, healthcare organizations and physicians are often tasked with making difficult decisions especially when balancing safe patient care with rationing medical equipment, interventions and

healthcare personnel [4]. In the United States, several institutions (i.e. States, Health Care Systems, Organizations) have made efforts to guide the allocation of resources towards the front-line workers [5-7]. One of the most notable efforts has been the cancellation of elective surgeries [5,6]. Although guidelines exist with regards to what cases should go to the operating room during a pandemic [7-10], many institutions rely on administrative decision-making committees to determine the suitability for surgery.

The purpose of this case report is to discuss the decision-making process, and resource utilization for spine cases that necessitate urgent surgical intervention in light of the COVID-19 pandemic.

<sup>1</sup>Department of Orthopaedic Surgery, Northwell Health Plainview Hospital, Plainview, NY, USA.


<sup>2</sup>Department of Orthopaedic Surgery, Huntington, Northwell Health Huntington Hospital, NY, USA.

<sup>3</sup>Donald and Barbara Zucker School of Medicine at Hofstra, Hempstead, NY, USA.

<sup>4</sup>Department of Orthopaedic Surgery, Long Island Jewish Valley Stream Hospital, Valley Stream, NY, USA.

### Address of Correspondence

Dr. Matthew J. Partan,  
Department of Orthopaedic Surgery, Plainview Hospital,  
888 Old Country Road, Plainview, NY, USA.  
E: mpartan@northwell.edu



Dr. Matthew J. Partan



Dr. Peter B. White



Dr. Randy M. Cohn



Dr. Gus Katsigiorgis



Dr. Kanwarpaul Grewal

© 2020 Trauma International | Available on [www.traumainternational.co.in](http://www.traumainternational.co.in) | DOI- 10.13107/ti.2020.v06i02.104

This is an Open Access article distributed under the terms of the Creative Commons Attribution Non-Commercial License (<http://creativecommons.org/licenses/by-nc/3.0>) which permits unrestricted noncommercial use, distribution, and reproduction in any medium, provided the original work is properly cited.

**Case Presentation:**

J.O. is a twenty-five-year-old Hispanic male who presented to an emergency department in Long Island, New York on March 30<sup>th</sup>, 2020 with a chief complaint of low back pain with associated leg weakness and difficulty with urination. Notably, the date of injury occurred just two weeks after the health system canceled all elective surgeries due to the COVID-19 pandemic. He described a three-day history of primarily low back pain that began suddenly after “a sneezing episode”. The patient reported the onset of low back pain immediately after the sneezing event, which insidiously progressed to bilateral leg numbness and tingling. He was evaluated at an orthopedic urgent care on the date of onset and started on a Medrol Dose Pack. These symptoms failed to improve with the use of the prescribed steroids and he additionally reported having episodes of difficulty with urination later that day (roughly 48 hours prior to emergency room presentation). His pain substantially progressed permitting his ability to ambulate with a pronounced sense of left leg weakness. He additionally complained of progressive loss of sensation over the plantar aspect of his left foot. He denied any other associated trauma, fevers, chills, or any constitutional symptoms. There were no episodes of stool incontinence or any complaints of subjective saddle anesthesia. He denied any recent exposure to COVID-19, travel outside of the state, or any respiratory complaints. The patient reported a history of well controlled asthma and a remote history of low back pain that resolved with an epidural injection years ago. He denied any previous surgical history, tobacco or alcohol abuse. On the morning prior to his emergency room visit, the patient was evaluated as an outpatient by an orthopedic surgeon, and due to his urinary complaints was sent in for evaluation for concerns of impending cauda equina syndrome (CES).

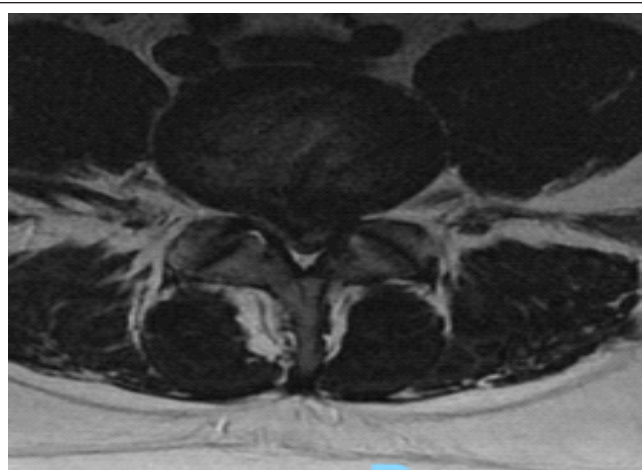
On examination, he displayed stable vital signs without any fever. He had diffuse lumbar spine paraspinal tenderness to palpation and was unable to ambulate due to back and left leg pain. His neurological exam demonstrated left lower extremity 5/5 manual muscle testing except for the L4 and L5 motor distributions showing 4/5 strength. There was decreased sensation to light touch of the S1 dermatome, but otherwise normal sensory exam of the left lower extremity. Right lower extremity examination showed 5/5

manual muscle testing throughout with sensation intact to light touch in L2-S1 distribution. He did not demonstrate any upper motor neuron signs and his rectal examination showed sensation to be intact throughout with appropriate active and passive rectal function. The remainder of his neurological examination was unremarkable.

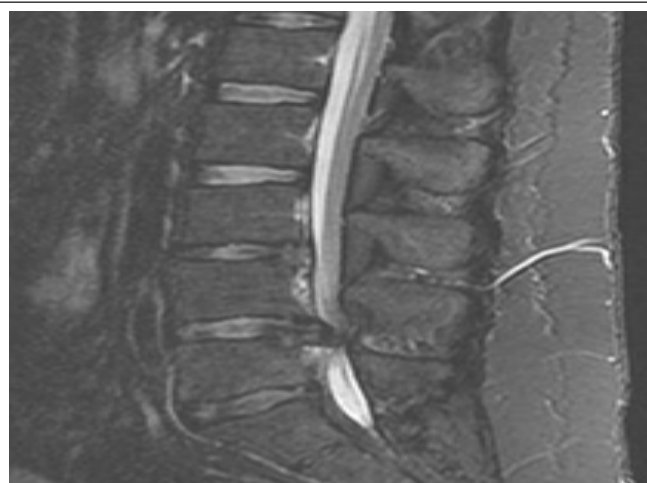The patient was seen and examined by the orthopedic surgery resident who made a preliminary diagnosis of incomplete cauda equina with altered bladder function. An MRI revealed a moderately large central disc extrusion of L4/5 with deformation at the ventral thecal sac which resulted in severe spinal stenosis (Fig. 1, Fig. 2). The disc height and signal was relatively preserved at L4-5 with discogenic sclerosis in the dorsal endplates. There was no migrating free fragment or significant foraminal stenosis.

In light of the COVID-19 pandemic, a lengthy discussion was had with the patient regarding the urgency of his diagnosis and necessity of surgical intervention to prevent worsening and/or chronic neurological deficits; Additionally, risks of COVID-19 transmission were reviewed. The patient had a COVID-19 PCR drawn in the emergency room which remained pending during the eventual operative procedure. As per hospital protocol, the attending orthopedic surgeon reviewed the case with the hospital's perioperative surgical committee regarding the urgent nature of the case. Due to hospital occupancy and time constraints on anesthesia's availability, the transfer to a nearby hospital within the system was initiated to facilitate timely operative intervention. The operative surgeon was granted emergent rights to perform surgery at the other hospital. Given the infrastructure and previous planning of our healthcare system, the ability for a quick and efficient timely transfer was executed without complication or delay in care.

Upon transfer to the affiliate hospital, the patient successfully underwent an L4/5 decompression and microdiscectomy for a large extruded disk herniation at L4/5 level without complications. From the time of his initial presentation to the emergency room he was successfully transferred and brought to the operating room suite within eight hours. On postoperative day one, the patient was noted to have complete resolution of his left leg weakness with notable return of normal urinary function. His dressing was clean and dry



**Figure 1:** Sagittal T2-Weighted MRI



**Figure 2:** Axial T2-Weighted MRI

**Figure 1 & 2:** Moderately large central disc extrusion of L4/5 with deformation at the ventral thecal sac which resulted in severe spinal stenosis

with a drastic improvement of his neurological exam demonstrating 5/5 manual muscle motor testing and sensation was grossly intact throughout. He successfully ambulated with physical therapy and was discharged home on the evening of postoperative day one. The patient's COVID-19 test results came back negative on post operative day two and the patient was notified by phone of his results.

At two-week follow up, the patient was seen in the office. Masks and gloves were worn by both provider and patient. Patient had no acute complaints, with resolution of all prior symptoms. Patient demonstrated 5/5 manual motor testing and sensation was grossly intact throughout.

### **Discussion:**

The unexpected arrival of COVID-19 has quickly altered the framework of our health care system by placing substantial strain on healthcare resources [11]. Many institutions have developed guidelines and committees to guide surgical care as a result of this change [7-9]. As evidenced by this case, the infrastructure of each hospital during this time may not permit surgical intervention in a timely fashion. In normal times the decision-making in this case may seem straightforward; however, this case demonstrates the strains that the COVID-19 pandemic placed on our healthcare system [1] especially with regards to surgical acuity, COVID-19 exposure risk and resource allocation.

In this case, the necessity for operative intervention was clear; however, the logistical barriers with resource availability and surgical acuity created a unique situation. The patient's clinical presentation with neurological deficits, mainly urinary dysfunction, undoubtedly required surgical decompression for optimal outcomes. Historically, bladder paralysis in the setting of cauda equina was considered the most important indication for immediate surgery [12]; however, more recent literature has challenged the traditional "emergency" of CES and thus the principle of immediate surgery for all CES patients remains elusive. Although there is some literature that supports early surgery following CES with urinary retention [13-19], there is lack of agreement that earlier decompression after CES with urinary retention improves outcomes [20, 21]. Some authors have suggested that emergency surgery should be reserved for those patients who have incomplete lesions who are neurologically deteriorating; whereas patients with CES with urinary retention can wait for as long as 24-48 hours [22]. Others have reported that delay to decompression can result in worse bladder outcomes [14]. With the varying literature in mind, we felt the young age of the patient, his acuity of onset and neurological progression all favored urgent decompression. As demonstrated in this case, surgeons managing CES are first faced with the difficult decision on the optimal operative timing, but during the current pandemic may have additional obstacles while executing the plan in a timely fashion.

An additional consideration is the risk of COVID exposure and transmission for the patient and providers. The decision to transfer the patient to a less affected hospital to decrease exposure risk was easy. Studies have suggested that nearly 12% of patients who test positive for COVID-19 are asymptomatic [23, 24]. The principal means of reducing the risk of asymptomatic transmission is testing. Although the patient did not have symptoms of COVID-19, we also

had to assume that the patient could be an asymptomatic carrier and could transmit the virus to healthcare providers. Despite national or organization recommendations for testing preoperative patients, we opted to test the patient in hopes of minimizing his risk of transmission as well as assess his risks for postoperative complications [25, 26]. At the time, COVID testing resulted in greater than 24 hours. Prior to the rests resulting, a collaborative decision was made to proceed with surgery largely due to the progressive neurological decline and patients' low risk for having symptomatic COVID. This case demonstrates that surgeons treating patients with progressive neurological compromise due to spinal pathology are faced with moral dilemmas in regards to obstacles such as COVID-19 status that may permit timeliness to surgical decompression.

Governments, international agencies and health systems have an obligation to ensure, to the best of their ability, adequate provision of health care for all [27]. Unfortunately, amidst the COVID-19 pandemic, the ethical dilemma of resource allocation becomes substantially magnified. Resource allocation should be guided by well established, broadly applicable ethical principles, unless there are characteristics of the outbreak that justify different courses of action [27]. Due to the unequal distribution of cases in our region, our system quickly adapted and adopted various guidelines and committees to organize resource allocation. In our case example, the original presentation unfortunately took place at a hospital with a significant percentage of COVID-19 positive patients and scarce personnel to adequately provide care. In order to offset the inequality of maximum resource utilization, a parallel transfer to an affiliated hospital with more readily available resources appeared to be the correct choice for multiple reasons. Having a transfer process in place for patients that require care unable to be carried out at a displaced facility allows the organization to display accountability in their actions. Fair allocation of resources at particularly affected hospitals helps maintain ethical principles while also maintaining justice.

### **Conclusion:**

With our healthcare system in the epicenter of the COVID-19 pandemic, we are in a unique environment exposed to the harsh characteristics of the surge. As demonstrated in this case, the displacement of immediately available resources, such as anesthesia staff, placed strain on the routine workings of surgical coordination. The transparent relationship of the attending surgeon and perioperative COVID-19 committee allowed free discussion regarding collaboration on the best justice based solution. A shared discussion weighing the risks and benefits, as well as the urgency of operative intervention, concluded that an expedient parallel transfer would be the best solution to maintain distributive justice and beneficence.

### **Clinical Message:**

Given the continued effects of the COVID-19 pandemic on the country's healthcare systems, our experiences in New York state can help other regions impacted by disease burden. Our case example can help other similar health systems learn from our successful use of resources. In addition, the commentary on ethical boundaries can be similarly helpful.



## References

- Richardson S, Hirsch JS, Narasimhan M, et al. Presenting Characteristics, Comorbidities, and Outcomes Among 5700 Patients Hospitalized With COVID-19 in the New York City Area. *JAMA*. Published online April 22, 2020. doi:10.1001/jama.2020.6775.
- Centers for Disease Control and Prevention. Coronavirus disease 2019 (COVID-19): cases in US. Accessed April 22nd, 2020. <https://www.cdc.gov/coronavirus/2019-ncov/cases-updates/cases-in-us.html>.
- Wu Z, McGoogan JM. Characteristics of and important lessons from the coronavirus disease 2019 (COVID-19) outbreak in China: summary of a report of 72 314 cases from the Chinese Center for Disease Control and Prevention. *JAMA*. Published online February 24, 2020.
- Emmanuel EJ, Persad G, Upshur R, et al. Fair Allocation of Scarce Medical Resources in the time of COVID-19. Published March 23, 2020; DOI: 10.1056/NEJMs2005114.
- Cuomo, A., 2020. Executive Order: Continuing Temporary Suspension And Modification Of Laws Relating To The Disaster Emergency. [online] <[https://www.governor.ny.gov/sites/governor.ny.gov/files/atoms/files/EO\\_202.10.pdf](https://www.governor.ny.gov/sites/governor.ny.gov/files/atoms/files/EO_202.10.pdf)> [Accessed 18 April 2020].
- Murphy, P., 2020. Executive Order 109. [online] <<https://nj.gov/infobank/eo/056murphy/pdf/EO-109.pdf>> [Accessed 18 April 2020]. (2020), Global guidance for surgical care during the COVID-19 pandemic. *Br J Surg*. doi:10.1002/bjs.11646
- ACS Statement on the Importance of Maintaining the Emergency Care System during the COVID-19 Pandemic, <http://facs.org/covid-19/clinical-guidance/statement-maintain>; 2020 [accessed 20 April 2020].
- Center for Medicare and Medicaid Services: Opening up America again. Accessed April 23rd, 2020. <https://www.cms.gov/files/document/covid-flexibility-reopen-essential-non-covid-services.pdf>
- Center for Medicare and Medicaid Services, 2020. Non-Emergent, Elective Medical Services, And Treatment Recommendations. [online] Available at: <<https://www.cms.gov/files/document/cms-non-emergent-elective-medical-recommendations.pdf>> [Accessed 18 April 2020].
- Pandemic influenza plan: 2017 update. Washington, DC: Department of Health and Human Services, 2017 (<https://www.cdc.gov/flu/pandemic-resources/pdf/pan-flu-report-2017v2.pdf> opens in new tab). Accessed April 20th, 2020.
- Emanuel, Ezekiel J., et al. Fair Allocation of Scarce Medical Resources in the Time of COVID-19. *NEJM*: 2020; [www.nejm.org/doi/full/10.1056/NEJMs2005114](http://www.nejm.org/doi/full/10.1056/NEJMs2005114).
- Dinning, T A. R., and H. R. Schaeffer. Discogenic Compression Of The Cauda Equina: A Surgical Emergency. *ANZ Journal of Surgery*; 1993(63): 927-924., doi: 10.1111/j.1445-2197.1993.tb01721.x.
- Chau AMT, Xu LL, Pelzer NR, Gragnaniello C. Timing of surgical intervention in cauda equina syndrome: a systematic critical review. *World Neurosurg* 2014;81:640–50.
- N. V. Todd & R.A. Dickson (2016) Standards of care in cauda equina syndrome, *British Journal of Neurosurgery*, 30:5, 518-522.5
- Srikandarajah N, Boissaud-Cooke MA, Clark S, Wilby MJ. Does early surgical decompression in cauda equina syndrome improve bladder outcome? *Spine (Phila Pa 1976)* 2015;40:580–3. doi:10.1097/BRS.0000000000000813
- Shapiro S. Medical realities of cauda equina syndrome secondary to lumbar disc herniation. *Spine* 2000;25:348–52.
- Todd NV. Cauda equina syndrome: the timing of surgery probably does influence outcome. *Br J Neurosurgery* 2005;301–6.
- Jerwood D, Todd NV. Re-analysis of the timing of cauda equina surgery. *Br J Neurosurg* 2006;20:178–9.
- Todd NV. Causes and outcomes of cauda equina syndrome in medicolegal practice: a single neurosurgical experience of 40 consecutive cases. *Br J Neurosurg* 2011;25:503–8.
- Gleave JRW, Macfarlane R. Cauda equina syndrome: what is the relationship between timing of surgery and outcome? *Br J Neurosurg* 2002; 16:325–8.
- Gleave JRW, Macfarlane R. Prognosis for recovery of bladder function following lumbar central disc prolapse. *Br J Neurosurg* 1990;4:205–10
- McLain RF, Agrawal BM, Silverstein MP. Acute cauda equina syndrome caused by a disk herniation-is emergent surgery the correct option? *Surgical decompression remains the standard of care. Spine (Phila Pa 1976)* 2015;40:639–41. doi:10.1097/BRS.0000000000000848.
- Zhu, J., Ji, P., Pang, J., Zhong, Z., Li, H., He, C., Zhang, J. and Zhao, C., 2020. Clinical characteristics of 3,062 COVID-19 patients: a meta-analysis. *Journal of Medical Virology*.
- Bai Y, Yao L, Wei T. Presumed asymptomatic carrier transmission of COVID 19. *JAMA*. Epub ahead of press
- Lie SA, Wong SW, Wong LT, Wong TGL, Chong SY. Practical considerations for performing regional anesthesia: lessons learned from the COVID-19 pandemic. *Can J Anaesth*. 202 Mar 24.
- Lei S, Jang F, Su W, et al. Clinical characteristics and outcomes of patients undergoing surgeries during the incubation period of COVID-19 infection. *EClinical Medicine*. [Epub ahead of press]
- The origin, transmission and clinical therapies on coronavirus disease 2019 (COVID-19) outbreak – an update on the status. *Mil Med Res*. 2020 Mar;7(1):11.

**Conflict of Interest:** NIL

**Source of Support:** NIL

**Acknowledgment:** Northwell Health COVID-19 Research Consortium

### How to Cite this Article

Partan MJ, White PB, Cohn RM, Katsigiorgis G, Grewal K | Resource Utilization and Ethics of Urgent Orthopedic Spine Surgery During the COVID-19 Pandemic: A Case Report | *Trauma International* | July-December 2020; 6(2): 07-10.