

# A Rare and Atypical Case Report of Combined Rupture of Patellar Tendon, Anterior Cruciate Ligament, Medial Collateral ligament, and Lateral Meniscus Managed Operatively

Naveen Mittal<sup>1</sup>, Robin Bohat<sup>1</sup>, Ankush Jindal<sup>1</sup>, Akash Singhal<sup>1</sup>

## Abstract

**Introduction:** Extensor mechanism disruption with other ligament injuries at knee is rare. Rupture of the patellar tendon (PT) usually occurs at the inferior pole of patella leading to proximal retraction of 3–5 cm due to contraction of quadriceps. The medial collateral ligament (MCL) is the most frequently damaged ligamentous stabilizer of the knee. MCL injuries do occur as isolated lesions or in combination with damage to other ligamentous structures (meniscus and/or cruciate ligaments). Non-operative treatment is reasonable for the second-degree and some third-degree tears, but when they occur in conjunction with meniscal tears, they are best treated by surgical repair. The incidence of meniscal tears with acute anterior cruciate ligament (ACL) injuries ranges from 50% to 70%. The risk of lateral meniscus (LM) injury is high in ACL deficient knee as a result of abnormal loading and shear stress. However, simultaneous rupture of both the PT, ACL, MCL, and LM is a relatively rare injury. Our is a case of a 60-year-old male with a history of roadside accident presenting with simultaneous PT, ACL, MCL, and LM injury. We managed the patient with acute repairing of the PT with Ethibond no.5 sutures protected with stainless steel wire and the MCL repaired with Ethibond no.5 sutures. The ACL was not repaired as the limited literature has shown high incidence of arthrofibrosis in acute repair (Shelbourne et al.). Complex tear of anterior horn of LM was seen and was shaved off. We were able to achieve full extension at 3 months. In conclusion, we want to highlight the rarity of such injuries favoring the immediate repair of PT and delayed repair of ACL for achieving optimal results. The use of our treatment algorithm may facilitate clinical decision-making in an attempt to restore stability, preserve ROM, and maximize return to activity.

**Keywords:** Patellar tendon, Anterior cruciate ligament, Medial collateral ligament.

## Introduction

Patellar tendon (PT) rupture or extensor mechanism disruption with multiligaments injury at knee is rare [1]. There are reports mentioning the PT rupture with other knee ligaments injuries in literature [2, 3], but reports mentioning the anterior cruciate ligament (ACL), PT, medial collateral ligament (MCL), and lateral meniscus (LM) injuries together and their treatment algorithm have been very rare. A few published case reports demonstrate how easy it is to miss a PT rupture or a knee ligament tear when these injuries occur simultaneously [3]. In such combined injuries, there is a strong possibility of misdiagnosis of one of the lesions as the examination of the knee may be difficult as other distracting injuries may take precedence and a thorough knee examination may initially be overlooked [3]. Once an evaluation is performed, focus may be drawn toward one injury and a simultaneous injury may be overshadowed [3]. Tsarouhas et al. [4] reviewed 13 cases from the literature and found that five ACL tear diagnoses and one PT diagnosis were

initially missed. Return of knee function by proper planning of timing of surgery, which all ligaments to operate, repair versus reconstruction, timing of ligaments reconstruction, and treatment options, is important [5]. No consensus has still been established for managing these problems, and our case is one of such rare entity which adds to the pool of managing multiligamentous injuries and aid in defining the management protocols for such type of injuries as because of their rare occurrence, a definite treatment protocol has not yet been established [6]. We present a case of a 60-year-old male with a roadside accident presenting with simultaneous PT, ACL, MCL, and LM injury.

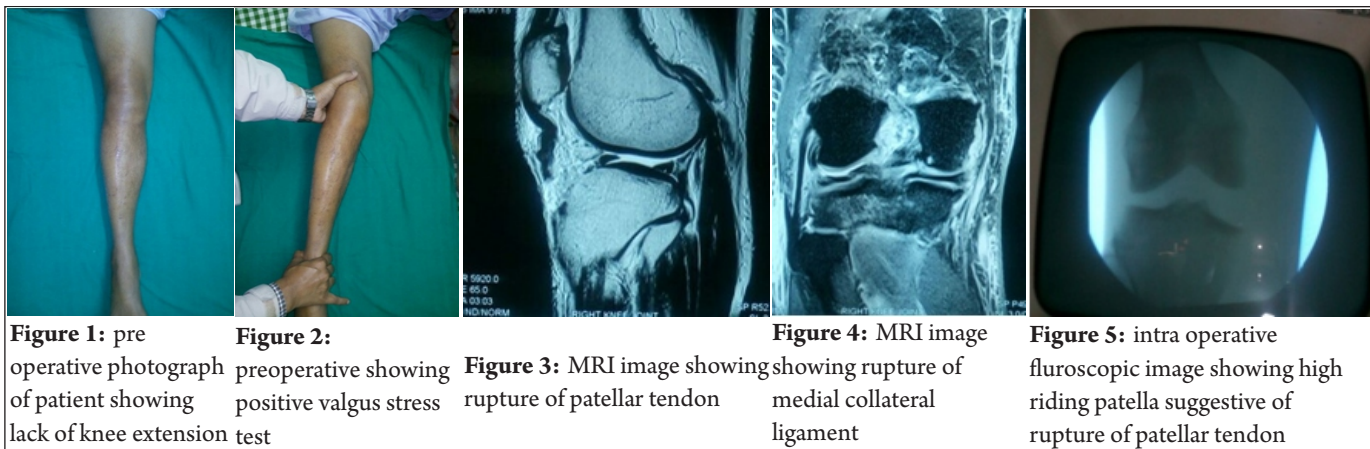
## Case Report

A 60-year-old male patient presented with roadside accident as a fall from bike sustaining a severe injury to his left knee. The patient was unable to ambulate immediately. The patient presented to us with pain and swelling in his left knee. On examination, active knee

<sup>1</sup>Department of Orthopaedics, Government Medical College Hospital Chandigarh

## Address of Correspondence

Dr. Naveen Mittal,  
#3732 Sector 46C, Chandigarh, India.  
Email: Naveen.mital0501@gmail.com



extension was zero (Fig. 1). A palpable gap was observed at the distal pole of PT attachment near the tibial tuberosity suggestive of a PT avulsion. Patellar tap was positive suggestive of knee effusion. On further examination, the patient had a positive Lachman test suggestive of ACL tear. The valgus stress test was positive for MCL tear (Fig. 2). Bragard test was positive for LM tear. Plain radiographs were negative for fracture but revealed superior displacement of the patella.

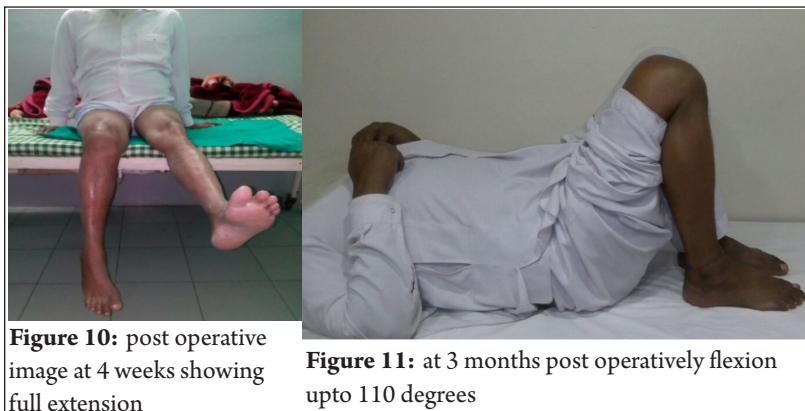
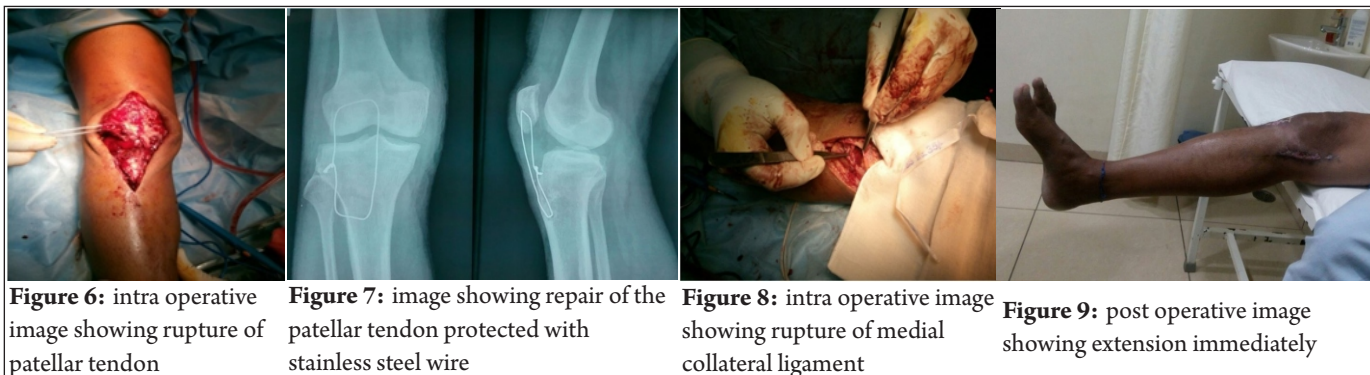
### Investigations

X-rays, ultrasound, and MRI were done. MRI showed avulsion of PT near the tibial tuberosity, complete tear of the ACL with buckling of PCL, medial collateral grade three tears, and LM tear (Fig. 3 and 4).

### Treatment

We planned the patient for acute repair of the PT and MCL and delayed repair of ACL. Our patient was operated under epidural anesthesia. Examination under anesthesia revealed laxity on valgus

stress again highlighting the MCL injury. The intraoperative fluoroscopic image showed high riding patella suggestive of PT rupture (Fig. 5). At first, we approached the PT through an anterior longitudinal midline incision (Fig. 6). After debridement of the tendinous tissue at the level of the tear, the PT was repaired. The two loops of the stitch were passed through two bony tunnels made vertically in the patella and sutured to each other at the proximal pole of the patella. Intraoperatively, the PT was repaired with Ethibond No. 5 sutures passed through the avulsed proximal pole. A trough was created at the tibial tuberosity and a transverse tunnel made. The ends of the suture were passed through the tunnel and tied back at the proximal pole. The repair was protected with a stainless steel wire passed through the upper pole of patella and tibial tuberosity tightened together (Fig. 7). The MCL was also repaired with Ethibond No.5 sutures checking for laxity with valgus stress test (Fig. 8). LM complex tear was shaved off. No demonstrable laxity was present.



### Outcome and follow-up

Postoperatively, the knee was placed in a hinged knee brace. Full weight-bearing was allowed immediately with the brace locked in full extension (Fig. 9). Knee range of motion was kept up to 45°. After 4 weeks, full extension was achieved (Fig. 10) and flexion was gradually progressed to 60° and then up to 110° at 12 weeks. At the latest follow-up at 3 months, the patient has full extension and up to 110 degrees of flexion (Fig. 11), and his ACL reconstruction was planned.

### Discussion

Multiligamentous injuries of the knee are rare with the most common reported pattern of combined injury of ACL and MCL. Combined rupture of the PT, MCL, and ACL is reported very sparingly with Levakos *et al.* reporting 6 cases with 2 cases of rupture of medial meniscus (MM), LM, MCL, ACL, and PT [7]. Costa-Paz *et al.* reported 3 cases of simultaneous rupture of ACL and PT [8]. Rae *et al.*, Chow *et al.*, and Futch *et al.* have reported individual case reports making a total of 15 cases reported so far [9, 10, 11]. Most of these injuries occurred as a result of indulgence in sports with only 3 cases occurring as a result of accidental injury [7, 8, 9, 10, 11]. In our study, the mode of injury was accidental suggesting a direct impact injury. Most of the patients in literature were in the age group of 20–30 years and mostly were male. Our patient was 60 years old. Only one patient who sustained an accidental injury as a result of fall from bike was 50 years old [7, 8, 9, 10, 11]. The rarity of combined ACL and PT injuries frequently lead to a delay in diagnosis or misdiagnosis. A PT injury can rapidly be diagnosed by clinical examination, but the presence of tense effusion makes diagnosis of other ligamentous injuries a challenge. The role of MRI for diagnosis of such rare injuries is also controversial. Of the 15 cases reported, MRI was done in 7 cases and not in 8 with MRI reserved for cases in which diagnosis was uncertain or the ones with atypical features. The harm of not performing an MRI lead to frequently missed ACL injury with no clear advantage. We performed MRI for describing the nature of all injuries [7, 8, 9, 10, 11]. The optimal treatment protocol has also met with controversy concerning the limited number of

cases reported. There is a general consensus on immediate repair of ruptured PT to restore knee extension with the delay in repair increasing the probability of poorer results. Simultaneous repair of the ACL was done in 5 out of 15 cases with 10 cases having no repair [7, 8, 9, 10, 11]. We preferred not to repair the ACL immediately. Simultaneous repair causes problems with rehabilitation increasing the risk of rupture of PT and increasing incidence of arthrofibrosis. Futch *et al.* reported immediate repair of the ACL leading to the complication of arthrofibrosis which necessitated arthroscopic lysis of adhesions and repeated closed manipulation. ACL reconstruction can be done at a later stage protecting the PT at the given time [11]. Merritt and Wahl presented a study on the treatment of 138 dislocated and multiligament injured knees [12]. Surgery of these knees is scheduled 2–3 weeks after the initial injury, and decision to surgically treat the MCL is made if during surgery an opening 8–10 mm is found in the medial compartment with valgus stress in 30° of flexion. We followed the same protocol and repaired the MCL as there was >10 mm of laxity.

### Conclusion

- Combined rupture of ACL, PT, MCL, and LM
- Acute repair of MCL and PT
- MRI for diagnosis
- Repair of PT protected with SS wire
- Delayed repair of ACL.

## References

1. Carroll BS, Cvetanovich G, Heyworth BE, Van de Velde S, Gill TJ IVth. Approach to management of the patient with the multiligament-injured knee. *Harvard Orthop J* 2013;15:54-64.
2. Gulabi D, Erdem M, Bulut G, Saglam F. Neglected patellar tendon rupture with anterior cruciate ligament rupture and medial collateral ligament partial rupture. *Acta Orthop Traumatol Turc* 2014;48:231-5.
3. Kim DH, Lee GC, Park SH. Acute simultaneous ruptures of the anterior cruciate ligament and patellar tendon. *Knee Surg Relat Res* 2014;26:56-60.
4. Tsarouhas A, Iosifidis M, Kotzamitelos D, Traios S. Combined rupture of the patellar tendon, anterior cruciate ligament and lateral meniscus: A case report and a review of the literature. *Hippokratia* 2011;15:178-80.
5. Brunkhorst J, Johnson DL. Multiligamentous knee injury concomitant with a patellar tendon rupture. *Healioorthopaedics* 2015;38:45-8.
6. Cox CL, Spindler KP. Multiligamentous knee injuries—surgical treatment algorithm. *N Am J Sports Phys Ther* 2008;3:198-203.
7. Levakos Y, Sherman MF, Shelbourne KD, Trakru S, Bonamo JR. Simultaneous rupture of the anterior cruciate ligament and the patellar tendon. Six case reports. *Am J Sports Med* 1996;24:498-503.
8. Costa-Paz M, Muscolo DL, Makino A, Ayerza MA. Simultaneous acute rupture of the patellar tendon and the anterior cruciate ligament. *Arthroscopy* 2005;21:1143.
9. Rae PJ, Davies DR. Simultaneous rupture of the ligamentum patellae, medial collateral, and anterior cruciate ligaments: A case report. *Am J Sports Med* 1991;19:529-30.
10. Chow FY, Wun YC, Chow YY. Simultaneous rupture of the patellar tendon and the anterior cruciate ligament: a case report and literature review. *Knee Surg Sports Traumatol Arthrosc* 2006;14:1017-20.
11. Futch LA, Garth WP, Folsom GJ, Ogard WK. Acute rupture of the anterior cruciate ligament and patellar tendon in a collegiate athlete. *Arthroscopy* 2007;23:112-e1.
12. Merritt AL, Wahl CJ. Rationale and treatment of multiple-ligament injured knees: the Seattle perspective. *Oper Techn Sports Med* 2011;19:5:1-72.

**Conflict of Interest: NIL**  
**Source of Support: NIL**

### How to Cite this Article

Mittal N, Bohat R, Jindal A, Singhal A. A Rare and Atypical Case Report of Combined Rupture of Patellar Tendon, Anterior Cruciate Ligament, Medial Collateral ligament, and Lateral Meniscus Managed Operatively. *Trauma International* Sep-Dec 2018;4(2):23-25.