

# Fixation of Acromion Fracture by Distal Radius Plate: A Case Report

Mohd Danish<sup>1</sup>, Hemant Gupta<sup>1</sup>, Ravi Kant<sup>1</sup>, Vikas Singh<sup>1</sup>

## Abstract

Acromion process fractures are as rare to happen and even rare to be treated surgically. Acromion acts as a stabilizer of shoulder joint through a number of ligaments and muscles attached to it. Although most of the acromion fractures are treated conservatively which may either be due to surgeon preference or lack of sufficient training in surgically treating these fractures. Our case is of a 54 years old, Male who presented to us after being referred from other hospital with Type II acromion process fracture who was treated surgically after the fracture was fixed by the unconventional distal end radius plate in place of usually used clavicular or recon plates. The patient yielded excellent Oxford shoulder score in the subsequent follow ups. Although the acromion fractures are not fixed by most of the surgeons and if at all they are fixed they usually use the conventional plates as mentioned for its fixation, but our case shows that even the distal radius plates can be used as a fixation device in such fractures with excellent rehabilitation results and almost no complications.

**Keywords:** Acromion, Fracture, Plate

## Introduction

Acromial fractures are rare fractures and account for 3-5% of all the orthopaedic fractures. Most of the acromial fractures can be managed non operatively. However, typically most of the acromial fractures are usually associated with other complex fractures around the shoulder joint but isolated acromial fractures are otherwise rare. Acromial fractures though managed conservatively in most of the cases but displaced fractures may cause decreased subacromial space and result in impingement along with the problems in shoulder joint movements. If managed operatively the acromion fractures are either fixed by TBW, cancellous screws or recon plates. This case report shows the fixation of a 54 years old male with isolated acromion fracture fixed by unconventional distal radius plate.

## Case Presentation

The patient is a 54 years old male who presented to our hospital's OPD after being referred from some other hospital with history of slip and fall at home. On further examination the patient had severe pain, ecchymosis, abrasions and swelling over the affected shoulder. An initial X-ray of the shoulder joint was done which revealed displaced fracture of the acromion process and was further classified as Kuhn Type II acromion fracture. (Fig. 1)

The patient was admitted and planned for surgery. An additional non contract CT of the injured shoulder was done so as to look the detailed morphology as well as to plan the surgical treatment. After routine preoperative investigations and pre anesthetic checkup/clearances the patient was taken up for surgery. The patient was placed in the lateral position after administering GA. The routine scrubbing, painting and

draping was done after which the bony landmarks viz the Greater tuberosity, the lateral end of clavicle, the lateral end of acromion and the blade of acromion was marked with a marking pen. The superior approach to the acromion was taken and an incision was placed extending from the midpoint of greater tuberosity aiming towards the scapular spine crossing just posterior to the anterior tip of acromion.

The subcutaneous tissue was incised and cleared thus exposing the underlying muscle fibers. One might have to release partially the deltoid anteriorly and the trapezius posteriorly in order to expose the full extent of the fracture. The neurovascular structure specially the course of axillary nerve should be kept in mid during dissection when extended inferiorly and implant placement. (Fig. 2)

After clearing the fracture ends of the hematoma and intervening soft tissue the fracture was reduced and held provisionally with the help of K wires. As the scapula is mostly a cancellous bone with less cortical component the implant fixation is a bit hard. Most of the times either acromion was held with the help of Wires as a tension band wiring construct or the help of cancellous screws. Some of the authors have even used a recon plate for the fixation of such fractures. Our case has been fixed with the help of a 2.7 mm distal radius plate, cortical and mostly locking screws. An additional K wire was left in situ passing through the acromion to provide extra strength and stability to the construct. (Fig. 3)

After regular wash the wound was closed in layers, the muscles end released were attached again to the ends followed by subcutaneous and skin sutures. Post operatively the patient's operated shoulder was placed in a shoulder immobilizer. The regular wrist and elbow ROM exercises were commenced on the next post-operative day followed by

<sup>1</sup>Department of Orthopaedics, Max Super Specialty Hospital, Vaishali, Ghaziabad, Uttar Pradesh, India.

## Address of Correspondence

Dr. Mohd Danish,

Department of Orthopaedics, Max Super Specialty Hospital, Vaishali, Ghaziabad, Uttar Pradesh, India.

E-mail: danish.shan@gmail.com

Submitted: 16/01/2023; Reviewed: 13/02/2023; Accepted: 25/04/2023; Published: 10/06/2023

Trauma International ISSN 2455-538X | Available on [www.traumainternational.co.in](http://www.traumainternational.co.in) | DOI- <https://doi.org/10.13107/ti.2023.v09.i01.35>

This is an open access journal, and articles are distributed under the terms of the Creative Commons Attribution-NonCommercial-ShareAlike 4.0 License <https://creativecommons.org/licenses/by-nc-sa/4.0/>, which allows others to remix, tweak, and build upon the work non-commercially, as long as appropriate credit is given and the new creations are licensed under the identical terms.

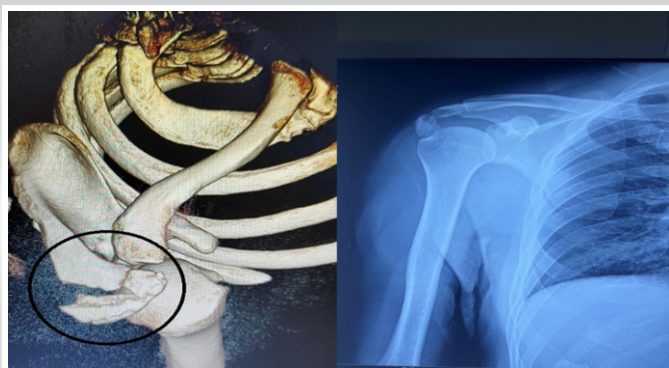

Figure 1: Pre-operative X-ray and 3D CT images

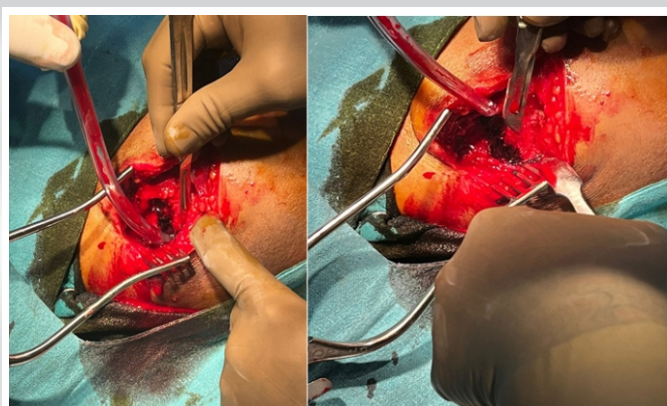


Figure 2: Intraoperative images showing dissection and fracture morphology

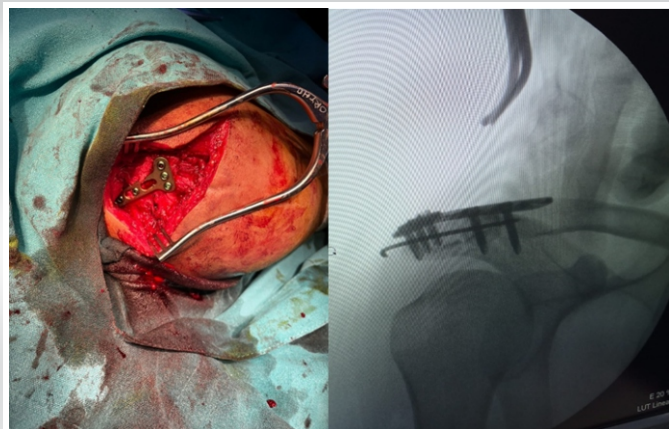


Figure 3: Final intra operative pictures showing final implant position

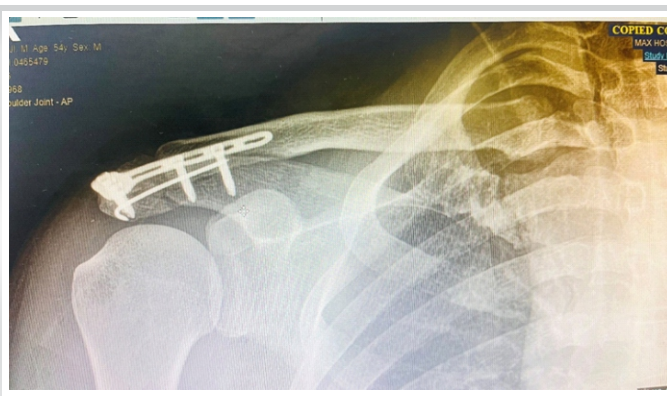

Figure 4: 1 month post-operative X-ray

discharge. The routine prophylactic antibiotics were given for the next 5 days along with some analgesics, although the patient experienced minimal to almost no pain post operatively. Sutures were removed on the 14<sup>th</sup> post-operative day along with starting the gentle pendulum and ROM exercises of the shoulder.

Patient was followed up at 2 weeks, 1 month, 3 month and 6 months respectively. The movements and rehabilitation were assessed with the help of Oxford shoulder score. The Oxford shoulder score went up from a score of 16 at the time of injury to 58 at the end of 6 months. The patient achieved full ROM at the operated shoulder joint with no signs or symptoms of impingement at the shoulder. (Fig. 4)

Post-operative X-rays were also done at post op day 1 along with the same at 1, 3 and 6 months respectively. The signs of union were seen at 3 months along with union fully achieved radiologically at the end of 6 months. There were also no signs of implant loosening, K wire back

out. Even the impingement of hardware was not experienced by the patient even after 6 months of surgery. (Fig. 5) (Fig. 6)

**Discussion**

Scapula positioned over the postero-superior aspect of the thoracic cavity along with the clavicle anteriorly acts as a strut to transmit the weight effectively from the axial to the appendicular skeleton. As scapula gives attachment to most of the muscles around the shoulder joint the effective fixation of fractures is very essential to achieve good ROM at the shoulder joint. Although most of the acromion fractures are treated conservatively but depending upon the classification, age and work profile of the patient operative treatment should be done effectively to achieve good rehabilitation. As discussed earlier the various treatment options that have been used, we took the Distal radius plate for its fixation. The horizontal limb of plate was placed and fixed over the distal part of fracture and vertical limb over the scapular blade. Depending on age, activity, and general condition of the patient, internal fixation is recommended in grossly displaced fractures of the acromion and coracoid process as concluded by Bauer et al. Hess et al. also concluded in their study that patient characteristics, such as activity level, might be a relevant parameter when selecting a treatment strategy.

**Conclusion**

As already mentioned that isolated acromion fractures are uncommon as these fractures are usually associated with other complex injuries of shoulder and these fractures are usually treated conservatively at most of the places. Acromion fractures however should be given a surgical

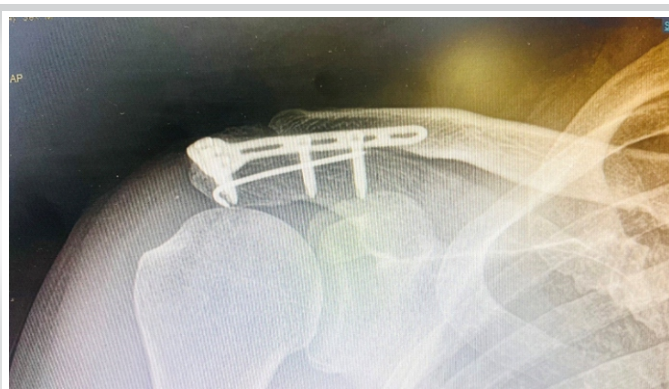

Figure 5: 3 months post-operative X-ray showing perfect union

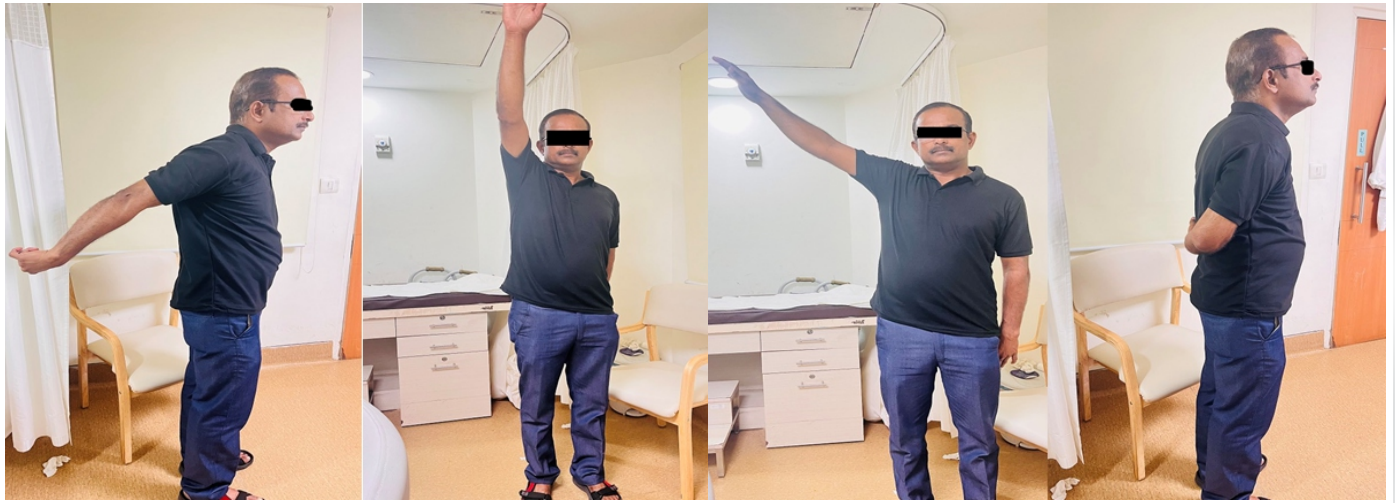

Figure 6: ROM of the operated shoulder at the end of 6 months

option at the places where they appear to be grossly displaced or there are radiological evidence of reduced sub acromial space, in future these displaced fractures may lead to signs of shoulder impingement along with early setting in of osteoarthritis of shoulder. The lifelong complaints of pain in the affected shoulder is a task to handle for both

the patient and clinician. In our case report we have mentioned such rare isolated acromion fracture which was fixed with an unconventional implant and yielded good post-operative union as well as rehabilitation.

**Declaration of patient consent:** The authors certify that they have obtained all appropriate patient consent forms. In the form, the patient has given his/her consent for his/her images and other clinical information to be reported in the Journal. The patient understands that his/her name and initials will not be published, and due efforts will be made to conceal his/her identity, but anonymity cannot be guaranteed.

**Conflict of Interest:** None, **Source of Support:** None

## References

1. Bartonicek J. Rockwood and Green's Fractures in Adults, 8th Edition. Vol. 1. Netherlands: Wolters Kluwer; 2015. Scapular fractures; p. 1478.
2. Cole PA, Shafiq B. Master Techniques in Orthopaedic Surgery. Vol. 1. Philadelphia: Lippincott Williams & Wilkins; 2006. Scapula fractures: open reduction internal fixation; pp. 15–36.
3. Scapular fractures. Analysis of 113 cases. Ada JR, Miller ME. 1991;269:174–180.
4. Fracture of the body, neck, or spine of the scapula. A long-term follow-up study. Nordquist A, Peterson C. 1992;283:139–144.
5. Pre- and postoperative function after scapula malunion reconstruction: a novel kinematic technique. Ganger EM, Ludwig PM, Wijdecks CA, Cole PA. J Orthop Trauma. 2013 Aug;27(8):e186–91.
6. Fractures of the acromion process: a proposed classification system. Kuhn JE, Blasier RB, Carpenter JE. J Orthop Trauma. 1994;8:6–13.
7. Operative treatment of scapular fractures: a systematic review. Lantray JM, Roberts CS, Giannoudis PV. Injury. 2008;39:271–283.

## How to Cite this Article

Danish M, Gupta H, Kant R, Singh V | Fixation of Acromion Fracture by Distal Radius Plate: A Case Report | January-June 2023; 9(1): 26-28 | <https://doi.org/10.13107/ti.2023.v09.i01.35>